



SCHIAB VETERINARY CENTER

Dr. László Siver Veterinarian

Hungary 2030 Érd, Földmunkás utca 79.

Phone: +36-23-378-219 Fax: +36-23-520-710 Mobil: +36-30-942-8815
www.schiab.hu siver@schlab.hu

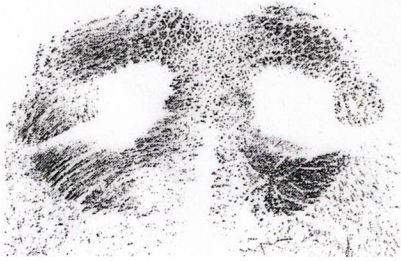
INTERNATIONAL VETERINARY CERTIFICATE OF HIP JOINT DYSPLASIA EXAMINATION

Examination No.: 1264-19486
Name of dog: Mikes Uti Tori
Date of birth: 31.12.2018.
Sex: Male
Owner: Paraszt László

Chip No.: 939000010939116
Breed: Bernese Mountain Dog
Pedigree No.: MET.Bsh.826/19
Address: HU-3000 Hatvan, Mikes út 34.

The undersigned veterinary surgeon certifies that identification number and chip number of the dog described above the same as the number is marked on the pedigree.

NOSE PRINT:



PEDIGREE:

Magyarországi Állatorvosok Egyesülete
EB SZÁRMAZÁSI IGAZOLÁS
CERTIFICATE OF ORIGIN FOR DOGS

ÁLLATÁLLÁMÁRA
SIGNATURE OF THE ISSUER

| | | | |
|--|-----------------------------|--|---|
| NÉV / NAME OF THE DOG: Mikes Uti Tori | | TÖRZSNEVÉNYÉLETSZÁMA / REGISTRATION NUMBER: MET.Bsh.826/19 | |
| SZÜLETÉSI ÉV / BIRTH YEAR: 2018 | HÓNAP / MONTH: 12 | NAP / DAY: 31 | ÓRA / HOUR: kan / male |
| SZÜLETÉSI HELYSZÍN / BIRTH PLACE: Hatvan | MÉRÉS / MEASUREMENT: 100 cm | SZÍNE / COLOUR: fekete / black | KIALAKULÁS DÁTUMA / DATE OF BIRTH: 2019.02.13 |
| FALLOSAZÁSI SZÁMA / REGISTERED ANIMAL NUMBER: Borsos Péter/utca / Bernese Mountain Dog, FC1-45 | | TARTÓZÁS HELYSZÍNE / ADDRESS: Paraszt László / 3000 Hatvan, Mikes u. 34. | |

| SZÜLŐK / PARENTS | NAPOSZÜLŐK / GRANDPARENTS | DEDSZÜLŐK / GREAT-GRANDPARENTS | ERKSZÜLŐK / GREAT-GREAT-GRANDPARENTS | |
|--|---|--|---|--|
| ♂ Mikes Uti Indian W520512081 MET.Bsh.826/19474 OTI-GI JEL. ENAG. DM.N.N. GCD.Fov. Eyre Ciel. HD.A. DM.FSP.N.N. ED.G. DNA #V702891 | ♂ Bernd von T Stokerybos J2B B09741050 1651203 PLO. P219.HDA Borsos Péter/utca | ♂ Eliabach von T Stokerybos L.O.S.165076050 Borsos Péter/utca | ♂ Hans-Max Fleck 8395117095 ♂ Niekkevaasen v Ondine 5099342203 ♂ Zentka von T Stokerybos 50581897652 ♂ Yasmin von T Stokerybos L.O.S.165081050 ♂ Gulliver Gutzkow ac Hisselows B 1822731 ♂ Rosé de Plages vt Rijkenspark BORSOS PÉTER/UTCA | |
| ♂ Mikes Uti Resurrex MET.Bsh.1912510 WS 5302554 DM.N.N. SP.RTX.G. ED.G. HD.G. CIA.A. P.H.D. CAT.G. PRA.G. MKSZ.HIF. MKSZ.ING. MKSZ. C.M. MKSZ.CIV. MKSZ.HIGH. GCD.Fov. DNA #V701856 | ♂ Mikes Uti Forever MET.Bsh.364312 MKSZ.CAC. MKSZ.OTI-GI. ED.G. GCD.F CIA.A.B.K.A.PRA.PRYG.Fov. DM.N.N. HDA Borsos Péter/utca | ♂ Larin Vt Rijkenspark PKR.LI.99281.NHS 268374 BORSOS PÉTER/UTCA ♂ Iris vom Gipfelmeer MET.Bsh.26111199 WS4096401 MKSZ.PRYG.Fov. CIA.A. MKSZ.PRA.G. PRA.G. HD.G. HD.G. Borsos Péter/utca | ♂ Indian Hills Her To The Throne WS06422502 & 60192295 BORSOS PÉTER/UTCA ♂ Zandrina's Jazmina S118242803 BORSOS PÉTER/UTCA ♂ Garibaldi Cierre Kralovstvo SPK 11370941 MKSZ.CAC. MKSZ.OTI-GI. PRA.G. HD.G. HD.G. Borsos Péter/utca ♂ Borzika v Ipejskej Kottiny SPK 11370941 BORSOS PÉTER/UTCA | ♂ Briliana vom Gipfelmeer 12643 5267 99 ♂ Indian Hills Inflante Justice WS03679451 ♂ Rosa's samantha Lagrand Ramme WS05404887 ♂ Zandrina's Hubert S541102091 ♂ Janpan Lad's Electra S0096858 ♂ Aron Edu C1265 1856256 ♂ Zuzi v Galatvho Dobra SHPR 8010274 ♂ Wakerles-Nagymedve Joker MET.Bsh.332558 ♂ Inku v Hecsveto Kibuka SHPK 89725991 |

Ratings base by the FCI issued measurement system.

A No signs of Hip Dysplasia

The femoral head and the acetabulum are congruent. The cranio-lateral acetabular rim appears sharp and slightly rounded. The joint space is narrow and even. The Norberg angle is about 105°. In excellent hip joints the cranio-lateral rim encircles the femoral head somewhat more in caudolateral direction.

B Near normal hip joints

The femoral head and the acetabulum are slightly incongruent and the Norberg angle is about 105° or The femoral head and the acetabulum are congruent and the Norberg angle is less than 105°.

C Mild hip dysplasia

The femoral head and the acetabulum are incongruent, the Norberg angle is about 100° and/or there is slight flattening of the cranio-lateral acetabular rim. No more than slight signs of osteoarthritis on the cranial, caudal, or dorsal acetabular edge or on the femoral head and neck may be present.

D Moderate hip dysplasia

There is obvious incongruity between the femoral head and the acetabulum with subluxation. The Norberg angle is more than 90° (only as a reference). Flattening of the cranio-lateral rim and/or osteoarthrotic signs are present.

E Severe Hip Dysplasia

Marked dysplastic changes of the hip joints, such as luxation or distinct subluxation are present. The Norberg angle is less than 90°. Obvious flattening of the cranial acetabular edge, deformation of the femoral head (mushroom shaped, flattening) or other signs of osteoarthritis are noted.

SchiAb Kft.
Állatorvosi Centrum
2030 Érd, Földmunkás u. 79.



INTERNATIONAL VETERINARY CERTIFICATE
OF HIP JOINT DYSPLASIA EXAMINATION
SCHIAB VETERINARY CENTER
DR. LÁSZLÓ SIVÉR VETERINARIAN

LT OF THE EXAMINATION:


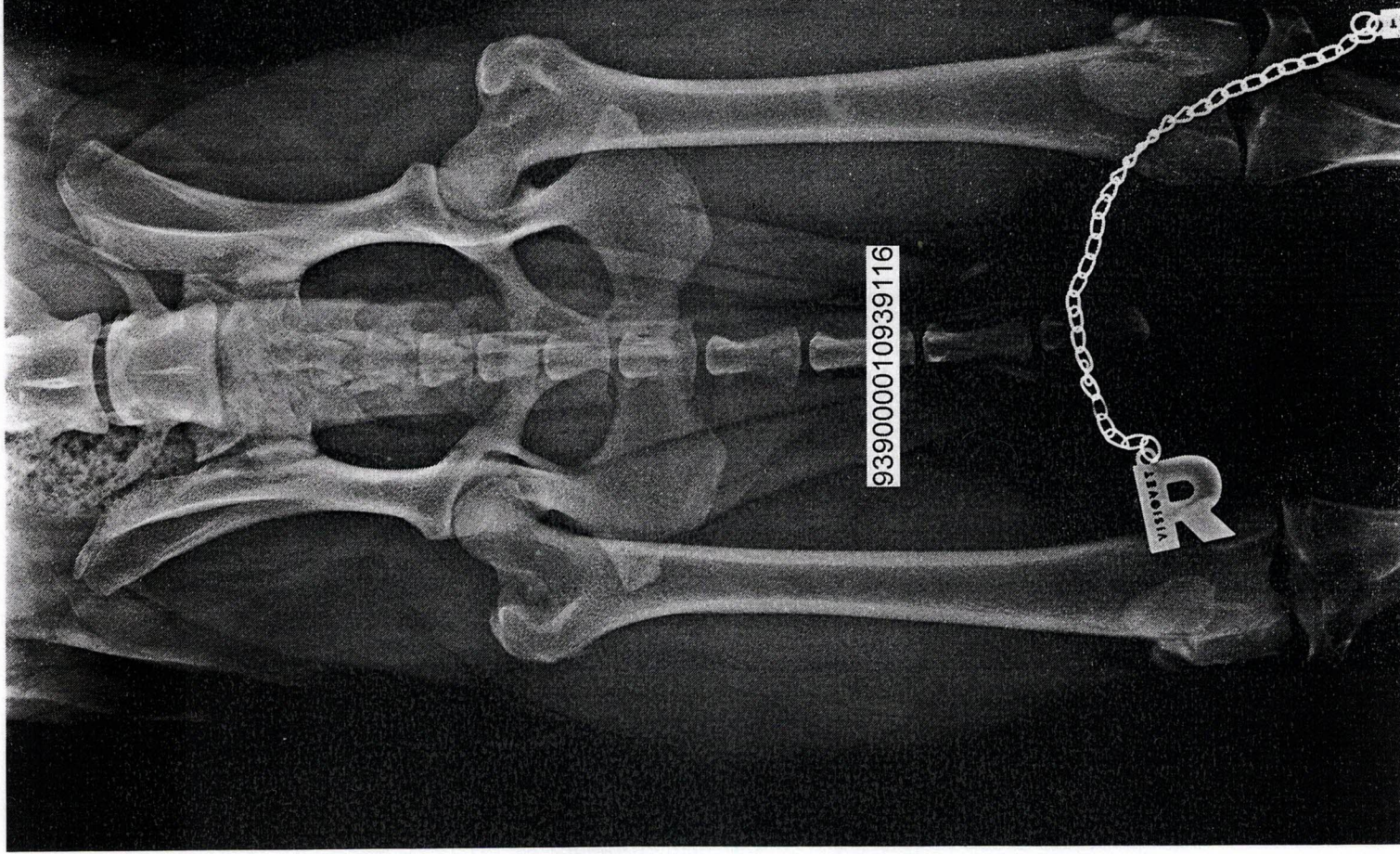
- asymmetrical
 insufficient
 insufficient
 deformed

 flat
 blurred with deposition
 flattened
 excentric
 subluxated
 luxated
 divergent
 less than 105 (left)
 less than 105 (right)

by the FCI issued measurement system

CONCLUSION:

| Germany (except SV) | Germany SV (GSD) | UK, AU, NZ (worse joint) | Switzerland (worse joint) | USA (OFA) |
|---------------------|----------------------------------|--------------------------|---------------------------|--------------------------|
| A1 | a, normal | 0 | 0 | excellent |
| A2 | a, normal | 1-3 | 1-2 | good |
| B1 | a, fast normal | 4-6 | 3-4 | good |
| B2 | a, fast normal | 7-8 | 5-6 | fair |
| C1 | a, noch zugelassen ¹⁾ | 9-12 | 7-9 | borderline ²⁾ |
| C2 | a, noch zugelassen | 13-18 | 10-12 | mild |
| D1 | D1 | > 18 | 13-15 | moderate |
| D2 | D2 | | 16-18 | moderate |
| E1 | E1 | | 19-21 | severe |
| E2 | E2 | | 22-24 | severe |



Schiab Kft.
Schiab Veterinary Center
2030 Érd, Földmunkás u. 79.
Dr. Sívér László állatorvos
sz.: 12370104-2-13 MAOK 1639
sz.: 12370104-2-13 MAOK 1639
vet.sivgn.: Dr. László Sívér